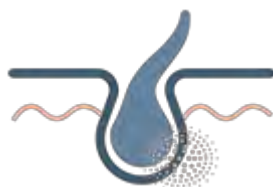


## Epidermolysis Bullosa

### Precision Panel



### Overview

Epidermolysis Bullosa (EB) is a group of genetic bullous disorders characterized by skin fragility and blistering of the skin and mucous membranes in response to minimal trauma. Although clinically and genetically very heterogeneous, it has been classified into four main types according to the layer of the skin in which blistering occurs: epidermolysis bullosa simplex, junctional epidermolysis bullosa, dystrophic epidermolysis bullosa and Kindler epidermolysis bullosa. The clinical heterogeneity results from the different distribution of the blisters, severity of cutaneous lesions and extracutaneous signs. Onset of symptoms usually occurs at birth or shortly after and is transmitted both in an autosomal dominant and recessive pattern.

The Igenomix Epidermolysis Bullosa Precision Panel can be used to make an accurate and directed diagnosis as well as a differential diagnosis of blisters ultimately leading to a better management and prognosis of the disease. It provides a comprehensive analysis of the genes involved in this disease using next-generation sequencing (NGS) to fully understand the spectrum of relevant genes involved.

### Indications

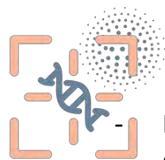The Igenomix Epidermolysis Bullosa Precision Panel is indicated for those patients with a clinical suspicion or diagnosis with or without the following manifestations:

- Superficial blisters with minimal trauma located in the mucosa: oral, nasopharyngeal, ocular, genitourinary, GI or respiratory
- Crusted erosions
- Family history of blistering disease
- Nail dystrophy

### Clinical Utility

The clinical utility of this panel is:

- The genetic and molecular confirmation for an accurate clinical diagnosis of a symptomatic patient.

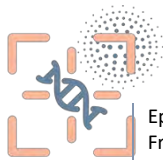

Early initiation of treatment with a multidisciplinary team in the form of medical care for optimization of wound healing, nutritional management, and surgical care for reconstruction or malignancy.

- Risk assessment and genetic counselling of asymptomatic family members according to the mode of inheritance.
- Improvement of delineation of genotype-phenotype correlation.

## Genes & Diseases

GENE	OMIM DISEASES	INHERITANCE*	% GENE COVERAGE (20X)	HGMD**
<i>ATP2C1</i>	Familial Benign Chronic Pemphigus	AD	99.95	210 of 210
<i>CD151</i>	Nephropathy With Pretibial Epidermolysis Bullosa And Deafness	AR	100	3 of 3
<i>CDSN</i>	Hypotrichosis, Peeling Skin Syndrome	AD,AR	99.88	12 of 13
<i>CHST8</i>	Peeling Skin Syndrome	AR	100	1 of 1
<i>COL17A1</i>	Junctional Epidermolysis Bullosa, Epithelial Recurrent Erosion Dystrophy	AD,AR	100	117 of 117
<i>COL7A1</i>	Autosomal Dominant Epidermolysis Bullosa Dystrophica, Autosomal Recessive Epidermolysis Bullosa Dystrophica, Epidermolysis Bullosa Pruriginosa , Epidermolysis Bullosa With Congenital Localized Absence Of Skin And Deformity Of Nails, Transient Bullous Dermolysis Of The Newborn, Acral Dystrophic Epidermolysis Bullosa, Centripetalis Recessive Dystrophic Epidermolysis Bullosa, Dominant Dystrophic Epidermolysis Bullosa, Epidermolysis Bullosa Simplex Superficialis , Generalized Dominant Dystrophic Epidermolysis Bullosa, Pretibial Dystrophic Epidermolysis Bullosa, Recessive Dystrophic Epidermolysis Bullosa Inversa	AD,AR	100	861 of 863
<i>CSTA</i>	Autosomal Recessive Exfoliative Ichthyosis, Ichthyosis Bullosa Ofsiemens-like, Acral Peeling Skin Syndrome	AR	100	5 of 5
<i>DSG1</i>	Congenital Erythroderma With Palmoplantar Keratoderma, Hypotrichosis, And Hyper-IgeE, Striate Palmoplantar Keratoderma	AD,AR	99.89	42 of 42
<i>DSG2</i>	Arrhythmogenic Right Ventricular Dysplasia, Familial Isolated Dilated Cardiomyopathy	AD	99.38	167 of 169
<i>DSG4</i>	Hypotrichosis Simplex, Monilethrix	AR	99.97	17 of 17
<i>DSP</i>	Arrhythmogenic Right Ventricular Dysplasia, Familial Dilated Cardiomyopathy With Woolly Hair And Keratoderma, Lethal Acantholytic Epidermolysis Bullosa, Keratosis Palmoplantaris Striata, Skin Fragility-Woolly Hair Syndrome, Carvajal Syndrome	AD,AR	99.91	366 of 369
<i>DST</i>	Autosomal Recessive Epidermolysis Bullosa Simplex	AR	99.08	19 of 19
<i>EXPH5</i>	Autosomal Recessive Epidermolysis Bullosa	AR	98.34	9 of 10
<i>FERMT1</i>	Kindler Syndrome	AR	99.83	78 of 81
<i>FLG2</i>	Peeling Skin Syndrome	AR	99.95	4 of 4
<i>GRIP1</i>	Fraser Syndrome	AR	100	17 of 17
<i>ITGA3</i>	Interstitial Lung Disease, Nephrotic Syndrome, And Congenital Epidermolysis Bullosa	AR	99.2	11 of 11
<i>ITGA6</i>	Epidermolysis Bullosa Junctionalis With Pyloric Atresia	AR	100	10 of 10
<i>ITGB4</i>	Epidermolysis Bullosa Junctionalis With Pyloric Atresia, Epidermolysis Bullosa Simplex, Weber-Cockayne Type , Junctional Epidermolysis Bullosa, Non-Herlitz Type, Aplasia Cutis Congenita, Bullosa	AD,AR	99.12	115 of 115
<i>JUP</i>	Naxos Disease , Lethal Acantholytic Epidermolysis Bullosa	AD,AR	100	56 of 56
<i>KLHL24</i>	Epidermolysis Bullosa Simplex, Generalized, With Scarring And Hair Loss	AD	99.96	8 of 8
<i>KRT1</i>	Bullous Erythroderma Ichthyosiformis Congenita Of Brocq, Ichthyosis Hystrix, Curth-Macklin Type , Cyclic Ichthyosis With Epidermolytic Hyperkeratosis , Keratosis Palmoplantaris Striata III, Palmoplantar Keratoderma	AD,AR	100	67 of 67
<i>KRT10</i>	Bullous Erythroderma Ichthyosiformis Congenita Of Brocq , Ichthyosiform Congenital Reticular Erythroderma, Ichthyosis, Cyclic Ichthyosis With Epidermolytic Hyperkeratosis, Autosomal Dominant Epidermolytic Ichthyosis	AD,AR	98.32	69 of 76
<i>KRT14</i>	Dermatopathia Pigmentosa Reticularis, Epidermolysis Bullosa Herpetiformis, Dowling-Meara Type, Autosomal Recessive Epidermolysis Bullosa Simplex, Epidermolysis Bullosa Simplex, Koebner Type , Epidermolysis Bullosa Simplex, Weber-Cockayne Type, Naegeli Syndrome,	AD,AR	100	132 of 132



GPDx

Genomic Precision  
Diagnostic  
by Igenomix

Epidermolysis Bullosa Simplex With Mottled Pigmentation, Naegeli-Franceschetti-Jadassohn Syndrome

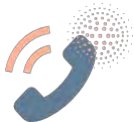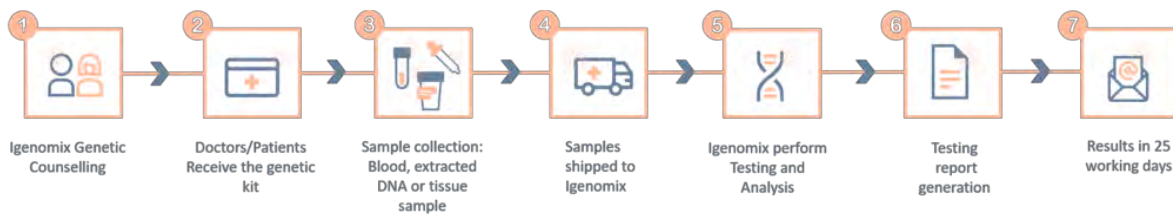
Igenomix®  
WITH SCIENCE ON YOUR SIDE

<b>KRT5</b>	Dowling-Degos Disease, Epidermolysis Bullosa Herpetiformis, Dowling-Meara Type, Epidermolysis Bullosa Simplex With Mottled Pigmentation, Autosomal Recessive Epidermolysis Bullosa Simplex, Epidermolysis Bullosa Simplex Koebner Type, Epidermolysis Bullosa Simplex, Weber-Cockayne Type, Epidermolysis Bullosa Simplex With Circinate Migratory Erythema, Epidermolysis Bullosa Simplex With Mottled Pigmentation, Epidermolysis Bullosa Simplex, Generalized Intermediate, Epidermolysis Bullosa Simplex, Generalized Severe, Localized Epidermolysis Bullosa Simplex	AD,AR	99.99	165 of 165
<b>LAMA3</b>	Junctional Epidermolysis Bullosa Herlitz Type, Junctional Epidermolysis Bullosa Non-Herlitz Type, Laryngoonychocutaneous Syndrome	AR	97.94	66 of 66
<b>LAMB3</b>	Amelogenesis Imperfecta, Generalized Hypoplastic Typemicrodontia Generalized, Junctional Epidermolysis Bullosa Herlitz Type, Junctional Epidermolysis Bullosa Non-Herlitz Type	AD,AR	99.99	119 of 120
<b>LAMC2</b>	Junctional Epidermolysis Bullosa Herlitz Type, Junctional Epidermolysis Bullosa Non-Herlitz Type, Junctional Epidermolysis Bullosa Inversa, Junctional Epidermolysis Bullosa Generalized Intermediate and Severe	AR	100	41 of 41
<b>MMP1</b>	Autosomal Recessive Epidermolysis Bullosa Dystrophica	AR	100	4 of 4
<b>PKP1</b>	Ectodermal Dysplasia/Skin Fragility Syndrome	AR	100	18 of 18
<b>PLEC</b>	Epidermolysis Bullosa Junctionalis With Pyloric Atresia, Epidermolysis Bullosa Simplex With Muscular Dystrophy, Epidermolysis Bullosa Simplex With Nail Dystrophy, Epidermolysis Bullosa Simplex Ogna Type	AD,AR	99.98	113 of 113
<b>SERPIN8</b>	Peeling Skin Syndrome	AR	99.87	3 of 3
<b>TGM5</b>	Acral Peeling Skin Syndrome	AR	100	26 of 26

\*Inheritance: AD: Autosomal Dominant; AR: Autosomal Recessive; X: X linked; XLR: X linked Recessive; Mi: Mitochondrial; Mu: Multifactorial.

\*\*Number of clinically relevant mutations according to HGMD

## Methodology



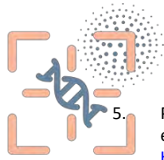
Contact us

Call +34 963 905 310 or send an email to [supportspain@igenomix.com](mailto:supportspain@igenomix.com) for any of the following objectives:

- Get more information about the test.
- Request your kit.
- Request a pick up of the kit after collecting the sample.

## References

1. Fine, J. D., Bruckner-Tuderman, L., Eady, R. A., Bauer, E. A., Bauer, J. W., Has, C., Heagerty, A., Hintner, H., Hovnanian, A., Jonkman, M. F., Leigh, I., Marinkovich, M. P., Martinez, A. E., McGrath, J. A., Mellerio, J. E., Moss, C., Murrell, D. F., Shimizu, H., Uitto, J., Woodley, D., ... Zambruno, G. (2014). Inherited epidermolysis bullosa: updated recommendations on diagnosis and classification. *Journal of the American Academy of Dermatology*, 70(6), 1103–1126. <https://doi.org/10.1016/j.jaad.2014.01.903>
2. Mariath, L. M., Santin, J. T., Schuler-Faccini, L., & Kiszewski, A. E. (2020). Inherited epidermolysis bullosa: update on the clinical and genetic aspects. *Anais brasileiros de dermatologia*, 95(5), 551–569. <https://doi.org/10.1016/j.abd.2020.05.001>
3. Lykova, S. G., Maksimova, Y. V., Nemchaninova, O. B., Guseva, S. N., Omigov, V. V., & Aidagulova, S. V. (2018). Vrozhdenyyi bulleznyy epidermoliz [Inherited epidermolysis bullosa]. *Arkhiv patologii*, 80(4), 54–60. <https://doi.org/10.17116/patol201880454>
4. Has, C., & Fischer, J. (2019). Inherited epidermolysis bullosa: New diagnostics and new clinical phenotypes. *Experimental dermatology*, 28(10), 1146–1152. <https://doi.org/10.1111/exd.13668>



GPD<sub>x</sub>

Genomic Precision  
Diagnostic  
by Igenomix

Igenomix®  
SCIENCE ON YOUR SIDE

5. Pfindner EG, Bruckner AL. Epidermolysis Bullosa Simplex. 1998 Oct 7 [Updated 2016 Oct 13]. In: Adam MP, Ardinger HH, Pagon RA, et al., editors. GeneReviews® [Internet]. Seattle (WA): University of Washington, Seattle; 1993-2021. Available from: <https://www.ncbi.nlm.nih.gov/books/NBK1369/>
6. Fine, J. (2010). Inherited epidermolysis bullosa: Past, present, and future. *Annals of the New York Academy of Sciences*, 1194(1), 213-222. doi:10.1111/j.1749-6632.2010.05463.x
7. Sawamura, D., Nakano, H., & Matsuzaki, Y. (2010). Overview of epidermolysis bullosa. *The Journal of Dermatology*, 37(3), 214-219. doi:10.1111/j.1346-8138.2009.00800.x
8. Fine JD, Eady RA, Bauer EA, et al. The classification of inherited epidermolysis bullosa (EB): Report of the Third International Consensus Meeting on Diagnosis and Classification of EB. *J Am Acad Dermatol*. 2008